

Case Report

# Kyphectomy in the treatment of patients with myelomeningocele

Sanjum Paul Samagh, MS<sup>a,\*</sup>, Ivan Cheng, MD<sup>b</sup>, Mark Elzik, MD<sup>c</sup>,  
Dimitriy G. Kondrashov, MD<sup>d</sup>, Lawrence A. Rinsky, MD<sup>e</sup>

<sup>a</sup>School of Medicine, University of California – Irvine, Medical Center, 101 The City Dr, Orange, CA 92868, USA

<sup>b</sup>Department of Orthopaedic Surgery, Stanford University, 900 Blake Wilbur Dr, Stanford, CA 94305, USA

<sup>c</sup>Department of Orthopaedic Surgery, University of California – Los Angeles, Box 956902, Room 76-143, Los Angeles, CA 90095-6902, USA

<sup>d</sup>St. Mary's Medical Center, Spine Center, One Shrader St, Suite 450, San Francisco, CA 94117, USA

<sup>e</sup>Department of Orthopaedic Surgery, Stanford University, 730 Welch Rd, 1st Floor, Palo Alto, CA 94304, USA

Received 3 May 2010; revised 14 December 2010; accepted 26 January 2011

## Abstract

**BACKGROUND CONTEXT:** Myelomeningocele kyphosis is a complex disorder that usually requires surgical intervention. Many complications can occur as a result of this disorder and its treatment, but only surgical correction offers the possibility of restoring spinal alignment.

**PURPOSE:** The purpose of this retrospective study was to summarize the surgical results, complications, and short-term and midterm outcomes for surgical correction of severe kyphosis using a consistent surgical technique.

**STUDY DESIGN:** This was a retrospective review of our database of pediatric patients with myelomeningocele and lumbar kyphosis who underwent kyphectomy with the use of the Warner and Fackler technique.

**PATIENT SAMPLE:** Eleven pediatric kyphectomy cases performed by a single surgeon from 1984 to 2009 were reviewed.

**OUTCOME MEASURES:** Outcome measures include imaging, kyphotic angle measurement, and physical examination.

**METHODS:** Patients underwent the Warner and Fackler technique of posterior-only kyphectomy and bayonet-shaped anterior sacral fixation.

**RESULTS:** The mean extent of kyphosis was 115.6° (range, 77–176°) preoperatively with a correction to 13.0° (range, 0–32°) postoperatively, and a reduction with an average of 102.6° (range, 65–160°), for an 88.7% correction. On an average, 2.0 (range, 1–6) vertebrae were resected. Immediately postoperatively and at follow-up, with an average of 67.2 months (range, 8–222 months), the average kyphosis angle was 13.0° (range, 0–32°). All patients undergoing the procedure were unable to lie supine preoperatively. All patients postoperatively could lie in the supine position. The functional outcome in patients and caretakers was rated very favorably because all patients and caretakers who provided feedback (9 of 11) reported that they were satisfied with the procedure and would undergo the procedure again if given the choice.

**CONCLUSIONS:** This technique has become the most effective surgical reconstruction in myelomeningocele kyphosis. Although significant complications can occur during and after the procedure, most patients had satisfactory postoperative outcomes and restoration of sagittal balance with high patient and parent satisfaction © 2011 Elsevier Inc. All rights reserved.

## Keywords:

Myelomeningocele; Kyphosis; Kyphectomy; Treatment; Warner and Fackler

FDA device/drug status: not applicable.

Author disclosures: IC (consulting, Medtronic; speaking/teaching arrangements, Stryker Spine; scientific advisory board, NuVasive; grants, Medtronic, Stryker Spine); DGK (trips/travel, AO Spine; other relationships, Kyphon).

\* Corresponding author. School of Medicine, University of California – Irvine, Medical Center, 101 The City Dr, Orange, CA 92868, USA. Tel.: (858) 352-6996; fax: (858) 693-0060.

E-mail address: sanjum@stanford.edu (S.P. Samagh)

## Introduction

Management of hyperkyphosis in patients with myelomeningocele is typically challenging with generally only a surgical correction offering the possibility of reasonable spinal alignment. This progressive deformity, thought to be secondary to a deficiency in the posterior bony elements of the spine in addition to lateral displacement of spine

extensors with unopposed effects of spine flexors, may cause an alteration in biomechanics in which the upper body tends to fall forward [1]. The purpose of this retrospective study was to summarize the surgical results, complications, and short-term and midterm outcomes for surgical correction of severe kyphosis using a consistent surgical technique. Our hypothesis was that a posterior-only kyphectomy using apical vertebral resection and bayonet-shaped anterior sacral fixation is an effective method of treatment for patients with myelomeningocele kyphosis and has an acceptable level of complications.

## Materials and methods

The technique we used in this study is that described by Warner and Fackler. After approval from our institutional review board, records for pediatric patients surgically treated with kyphectomy by the senior author (LAR) from 1984 to 2009 were obtained. Eleven pediatric patients (four males and seven females) with kyphosis and myelomeningocele treated with kyphectomy were included in this study. The average age of the patients at the time of procedure was 9.1 years (range, 6.5–13.0 years) (Table 1). The most common indication for surgery was skin breakdown and difficulty sitting or lying in the supine position. Data obtained from patients' charts and operative records included demographic data, indications for surgery, curve parameters, and intra- and postoperative complications. Operative data included estimated blood loss, transfusions, cell saver volume, number and location of vertebrae excised, and length of surgery. Radiographs of the thoracic and lumbar spine were available pre- and postoperatively to measure kyphotic angles and lumbar spine height (Fig. 1). The average length of follow-up was 67.2 months (range, 8–222 months). Satisfaction was assessed through direct patient and parent feedback during follow-up visits.

## Surgical procedure

The patient was positioned prone on simple transverse bolsters on a Jackson frame. A standard posterior midline exposure was performed. The prior scar from the original closure of the myelomeningocele was used for the approach along one edge only, but the entire scar was excised at the end of the procedure. The apex of the kyphotic deformity was exposed subperiosteally laterally beyond the laminar ridge. Anteriorly, the kyphotic apex was also exposed subperiosteally until a blunt Hohman retractor could be placed ventral to the apical wedge-shaped vertebrae. The thecal sac was transected just above the level of the planned osteotomy and doubly oversown with a nonabsorbable suture. A watertight closure was confirmed by Valsalva maneuver. The cephalad portion of the gibbus was resected during the osteotomy. The resection was performed by first removing the appropriate discs with rongeurs and elevator, carefully keeping the anterior longitudinal ligament intact to function as an anterior hinge. At least one entire vertebra was resected, usually more. After the initial osteotomy, an attempt was made to approximate the ends of the vertebral column. If the gibbus persisted, additional cephalad vertebrectomies were performed until the osteotomy gap could be closed with the restoration of a normal contour to the back. It was considered important to maintain at least both L4 and L5 inferiorly so as to have adequate inferior bony purchase in addition to the sacrum. Furthermore, moving cephalad to the apex allows one to diminish the compensatory thoracic hyperlordosis.

Once the resection was achieved, two 5.5-mm stainless steel rods were contoured into a bayonet shape. The anterior aspect of the sacrum was bluntly dissected with either a right angle clamp or a Penfield elevator through the S1 foramen. The caudal short arm of the bayoneted rod passed through the S1 foramen anterior to the sacrum. As the cephalad long end of the first rod was reduced to the spine, it provided a lordosing moment to the caudal fragment and reduced the gibbus to a neutral position. A second rod

Table 1  
Kyphotic angle preoperatively, postoperatively, and at follow-up

Case	Sex	Age (y)	Weight (kg)	Preoperative kyphosis (°)	Postoperative kyphosis (°)	Reduction (°)	Clinical follow-up (mo)	Age at follow-up (y)	Follow-up kyphosis (°)
1	F	10	28.1	110	14	96	50	14	14
2	F	8.5	25.8	124	5	119	94	16	5
3	F	4.5	12.5	95	0	95	222	23	0
4	M	8	20.7	107	32	75	96	15	32
5	F	6.5	11.5	104	0	104	117	17	0
6	F	9	32.4	160	0	160	60	14	0
7	F	9	15	77	12	65	24	11	12
8	M	9.5	34	101	16	85	46	14	12
9	F	10	26.5	112	15	97	12	11	15
10	M	12	58	106	25	81	10	13	25
11	M	13	26	176	24	152	8	14	28
Average		9.1	26.4	115.6	13	102.6	67.2	14.7	13

M, male; F, female.

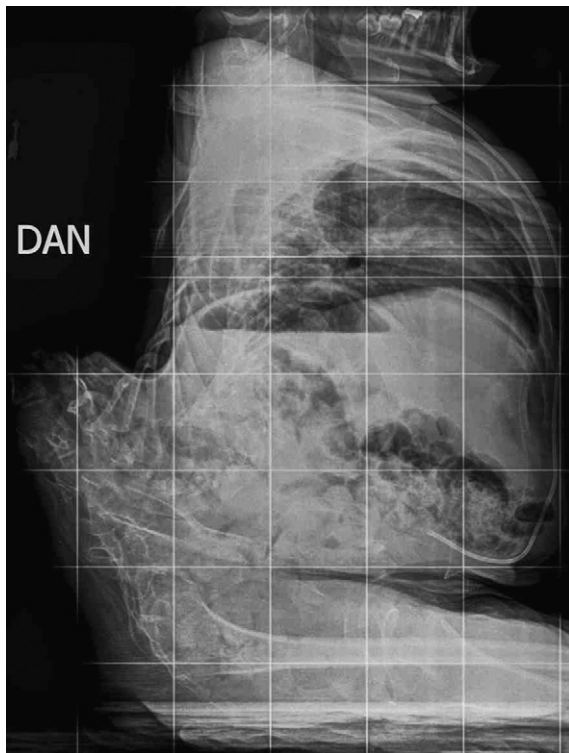


Fig. 1. Preoperative lateral radiograph of Patient 11.

was passed on the other side in a similar fashion. It was usually necessary to grasp both rods superiorly, levering down, and correcting gradually from inferiorly to superiorly. Although wires usually had to be left out at the apex (the junction of the closed canal to the open canal), wires were put in at almost every other level. Pedicle wires were used in the lower lumbar spine, and sublaminar wires were used above the vertebrectomy segment in the thoracic spine. The bone of the resected vertebrae was morselized, providing abundant autograft without the need for supplemental iliac autograft or allograft. The closure was performed over sub- and suprafascial drains, which were discontinued on postoperative Day 2.

## Results

The mean extent of preoperative kyphosis was  $115.6^\circ$  (range,  $77\text{--}176^\circ$ ) with a correction to  $13.0^\circ$  (range,  $0\text{--}32^\circ$ ) and immediately postoperatively, a reduction with an average of  $102.6^\circ$  (range,  $65\text{--}160^\circ$ ) clinically. Preoperative lumbar spinal height, measured as the inferior end plate of T12 to the most superior position of S1 was 8.2 cm (range, 5–13 cm). Postoperative lumbar spinal height was 10.3 cm (range, 8–13 cm), with an average increase of 2.1 cm (range, –1 to 5 cm). On an average, 2.0 (range, 1–6) vertebrae were resected. At final follow-up, with an average of 67.2 months (range, 8–222 months), the average kyphosis was  $13.0^\circ$  (range,  $0\text{--}32^\circ$ ). Three patients demonstrated a  $0^\circ$  loss of correction at final follow-up. A small amount of longitudinal growth of the spine along the rods was noted in most of the patients but was not specifically quantified.

Surgery took an average of 445 minutes (range, 265–582 minutes). The mean blood loss was 3,363 mL (range, 1,200–8,000 mL). Significant blood loss occurred despite the use of cell saver with an average intraoperative transfusion of 6.2 units (range, 3–12 units). Every patient required additional blood products, such as fresh frozen plasma, platelets, or both. Average percent of blood loss based on weight was 176% (range, 64.7–309%). Average blood loss *per kilogram* for the first three patients was 197 mL/kg; the average blood loss for the last three patients was 74.3 mL/kg. Minor complications included brief intraoperative hypotension in three of the patients. Hospital stay averaged 9.8 days (range, 8–15 days) (Table 2).

## Functional outcome

The functional outcome in patients and parents was rated very favorably because all patients and caretakers who provided feedback (9 of 11) reported that they were satisfied with the procedure. The other two patients or their caretakers could not be reached at the time of this review but were satisfied when last seen. Before surgical intervention, no patients were able to lie supine. All patients were able to

Table 2  
Patient surgical data and complications

Case	Estimated blood loss (cc)	Transfusion (units)	Cell saver	Length of surgery (min)	Vertebrae excised	Level(s) excised	Hospital stay (d)	Postoperative complications
1	5,500	8	1,800	427	3	L1–L3	13	
2	4,000	8	2,000	565	1	L2	11	
3	3,000	7	300	410	1	L1	15	Late decubitus (3 y)
4	1,300	4	400	512	1	L2	8	
5	1,200	3	145	510	1	L2	8	Late decubitus (9 y)
6	8,000	12	2,200	630	3	L1–L3	10	Femur fracture (4 y)
7	3,500	6	400	570	2	L1–L2	8	
8	3,000	8	700	690	1	L1	10	
9	2,500	4	830	593	1	L1	8	
10	3,000	5	1,300	480	2	L2–L3	8	Late decubitus (1 y)
11	2,000	3	2,000	630	6	T10–L3	9	
Average	3,363.6	6.2	1,097.7	547.0	2.0		9.8	

lie in the supine position postoperatively. All patients and parents contacted (9 of 11) stated that if given the choice, they would definitely undergo the surgical procedure again.

### Complications

No short-term complications other than excessive blood loss were noted in this study. Midterm complications included minor decubitus ulcers in three patients near the site of surgery ranging from 1 to 9 years later, likely unrelated to the surgical procedure. One of these required surgical intervention 3 years postoperatively for a skin flap. One patient experienced a femur fracture 4 years postoperatively treated with a splint.

### Discussion

A kyphotic deformity develops in up to 10% of patients with myelomeningocele, often with adverse outcomes without treatment [2]. This deformity, which typically occurs in the upper lumbar and lower thoracic region [3], is difficult and challenging, requiring careful intervention. The rate of progress of kyphosis in patients with myelomeningocele can be 8° to 12° per year [4]. With severe kyphosis, patients are unable to sit upright without the support of their hands, often sitting with a rib-against-thigh posture. Patients will present with difficulty in lying supine because of the prominent gibbus deformity in the back, making it an uncomfortable and often painful position to maintain. Moreover, the reduction in lumbar height secondary to kyphosis can result in a decrease in chest compliance with crowding of the abdominal contents onto the diaphragm. This leads to a compensatory adjacent hyperlordosis of the thoracic spine and further compromises already deficient respiratory function. In fact, the hyperlordosis is just as important to address as the kyphosis to maintain respiratory function. Additional comorbidities in these patients include urological difficulties stemming from the interference with urinary drainage leading to chronic urinary tract infections and sometimes a loss in the ability to self-catheterize. Scarred, thin, and poorly healing skin with repeated breakdown often occurs over the kyphotic areas, which can lead to frequent infections in the skin and leakage of cerebrospinal fluid (Fig. 2) [5].

Goals of surgery, as described by Eckstein and Vora [6] in 1972, included closure of the skin over the birth defect; restoration of more robust skin that is more resistant to ulceration; restoring the ability to sit or stand; reducing pressure on the abdominal wall to provide better access for potential subsequent urinary procedures and their diversions; relief of respiratory compromise; and relieving costal margin impingement on the pelvis causing pain and discomfort.

The techniques and instrumentations in the operative treatment of congenital kyphosis have evolved since its surgical origins. In 1968, Sharrard [7] first described

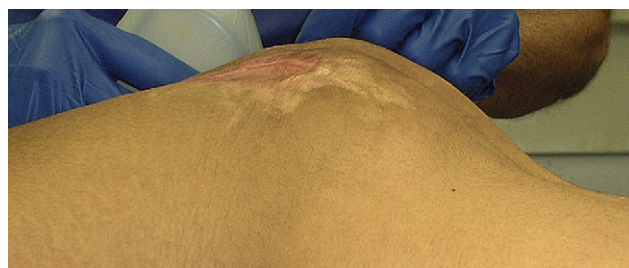

Fig. 2. Clinical photo of Patient 10 demonstrating the condition of the skin in the area of the previous myelomeningocele repair. The skin is often thin and friable, leading to repeated breakdown.

vertebrectomy as an operation to correct deformity and maintain the alignment. Lindseth and Stelzer [8] modified this technique in 1979. Both these techniques required postoperative external immobilization because there was limited internal instrumentation available at the time. Further advancement of the kyphectomy procedure was seen with Heydemann and Gillespie [9] in 1987, using a straight-line incision and anterior fixation of the spine to the pelvis to allow the patient to proceed quickly to an improved functional level. In 1989, McCarthy et al. [10] described an S-shaped rod technique fixed to the sacral ala to treat neuromuscular deformities, providing postoperative stability also without external immobilization. Warner and Fackler [11] refined the technique in 1993 by using Luque rod instrumentation with fixation through the first sacral foramina anterior to the sacrum and no postoperative immobilization, demonstrating an improved outcome over Harrington compression rods and spinal immobilization. This is the technique that we used in this study.

Most surgeons recommend operating between the ages of 5 and 12 years if the condition of the skin overlying the kyphotic deformity is adequate [12]. We suggest delaying the operation until the age of 8 years because earlier operative long fusions can restrict growth and chest wall development. In addition, smaller posterior elements in patients at a very young age make secure fixation more difficult.

Previous literature has demonstrated improvements in deformity after surgical correction via kyphectomy with more recent reports documenting much greater correction than earlier ones. The correction by Sharrard, who first described spinal osteotomy and arthodesis as a means of treating patients with myelomeningocele kyphosis, averaged 22° with a 2-year follow-up. Furderer et al. [13], using only vertebrectomies and transcorporeal screw fixations, demonstrated an average angle decrease of 47°. Heydemann and Gillespie achieved a decrease in the kyphosis angle of 91.2° pre- and postoperatively. Using a modified Gillespie technique, Huang and Lubicky [14] found that the preoperative kyphosis angle decreased 104.5°. More recently, McCall [15] used a modified Luque fixation on 16 patients with myelomeningoceles and kyphotic deformities and averaged an angle decrease of 96° at 5-year follow-up.



Our study used a posterior-only kyphectomy and bayonet-shaped anterior sacral fixation for the inferior anchorage of treatment. The average preoperative kyphosis was  $115.6^\circ$  with an initial postoperative kyphosis of  $13.0^\circ$ , an 88.7% correction. Only one patient, Patient 11, demonstrated a  $4^\circ$  increase in kyphotic angle measurement, considered within the error of measurement in our study. At follow-up, average correction for all patients remained at  $13.0^\circ$ , revealing no loss of reduction.

We did not measure the postoperative *thoracic lordosis* because the inferior vertebrae involved were often removed in the kyphectomy procedure. Nonetheless, most of our postoperative X-rays revealed some degree of residual *thoracic lordosis* (Fig. 3). We were conscious of the thoracic deformity and attempted to correct it but were unable to significantly correct the lordosis and kyphosis. In all cases, one, two, or three levels, just at the junction of the cephalad and caudal segment, were left unwired. This may have contributed to the residual *thoracic lordosis*.

Previous studies have historically demonstrated a loss of the initial correction. Sharrard reported an initial correction of  $33^\circ$  with an average loss of correction of  $11^\circ$  in 2 years. Litner and Lindseth reported a loss of correction of  $22^\circ$  at

latest follow-up. Nolden et al. [16] described a  $25^\circ$  loss of correction between the postoperative period and final follow-up. If significant kyphosis is left during the initial surgery, further progression is guaranteed. Once longer constructs and greater correction were obtained using more sturdy rods, loss of correction has lessened. For example, follow-up for Warner and Fackler as well as Huang and Lubicky demonstrated minimal difference in the kyphotic angle, with an average correction loss of  $3^\circ$  and  $2.7^\circ$ , respectively. Our study reveals maintenance of the decrease in the kyphotic angle at an average follow-up of 5.5 years with no average correction loss despite the use of “low tech” inexpensive implants.

Many authors have also described improved functionality of patients after kyphectomy operations. Furderer reported 13 of 14 patients returning to wheelchair mobility after surgery, whereas Heydemann and Gillespie found improved sitting posture in all 12 patients. McCall also found that all 16 of his patients had improved sitting posture combined with improved upper extremity function and independence. McMaster [17] found that all seven of his patients were able to sit erect without using their arms for support. Few have commented on ambulation because only a very small percentage of patients with a severe kyphosis have maximally assisted ambulation. None of our patients were able to walk preoperatively or postoperatively.

General complications of patients undergoing surgery with myelomeningocele kyphosis include delayed wound healing as high as 64%, blood loss higher than that in other comparable surgeries such as correction for idiopathic scoliosis, and even death [11,15,18]. Heydemann and Gillespie experienced complications such as cerebrospinal fluid leak postoperatively (self-resolving within 3 months), pseudoarthrosis secondary to instrumentation failure, and one case of rod dislodgment from the pelvis. McCall reported complications in half of his patients, including transient headache, superficial wound breakdown, a late skin infection, which required hardware removal, and supracondylar femur fractures. McMaster described the femur fractures as secondary to disuse osteoporosis after the extended amount of time without movement. McMaster also described implant failure in 4 of his 10 patients mostly related to the use of nonsegmental Harrington rods instrumentation. Thomsen et al. [19] reported two implant complications using the Warner and Fackler technique in nine children with myelodysplasia. Akbar et al. [20] found nine rod failures in 28 patients who underwent kyphectomy using the same procedure.

This study reports no major postoperative complications with patients, with the exception of decubitus ulcers. These ulcers occurred at the earliest 1 year postoperatively and were thought to be unrelated to the surgical procedure given the time frame. The skin in the area of the gibbus deformity is friable pre- and postoperatively because of not only tenting of the skin over the bony elements but also secondary to previous procedures for wound closure (Fig. 4).

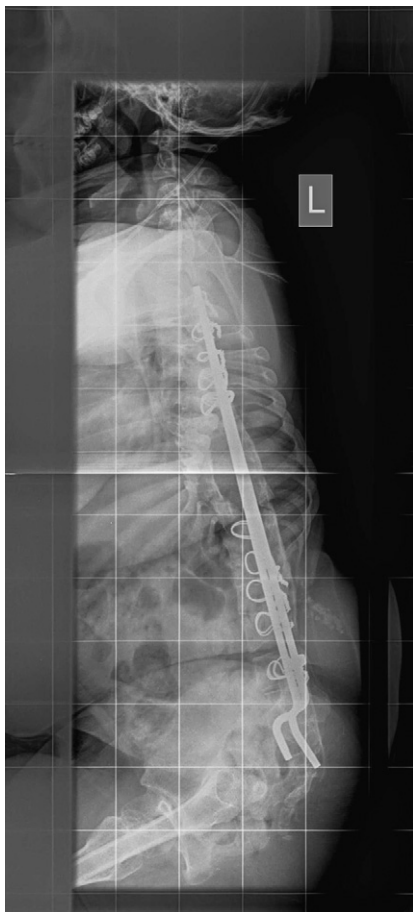

Fig. 3. A postoperative plain lateral radiograph of Patient 8 demonstrating residual thoracic lordosis after apical kyphectomy and instrumentation.

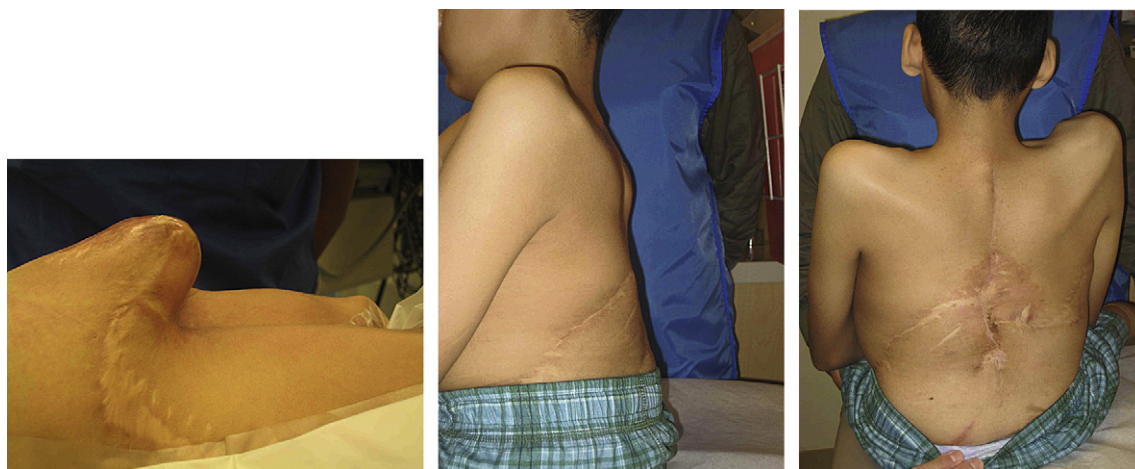


Fig. 4. Clinical photographs of Patient 11. (Left) Preoperative lateral photograph, (Center) postoperative lateral view, and (Right) postoperative posterior view.

Surprisingly, there were no surgical infections in this series. It is imperative that during the kyphectomy procedure the instrumentation is deeply inset and covered with paraspinal musculature, or sturdiest available scar tissue, given the thinness of the preoperative skin overlying the deformity. In addition, excising any previous scar *at the end* of the procedure ensures that fresh tissue is used for closure. This helps to prevent any additional skin breakdown and reduces the incidence of postoperative decubitus ulcers. An additional complication seen in this series was femur fracture at 4 years postoperatively. This complication required no surgical intervention and was treated with a pillow splint for correction.

In our case, all patients postoperatively were able to lie in the supine position, whereas none of them could lie in the supine position before surgery. This is an achievement for patients who previously had never been able to lie on their back, and it is one of the primary goals of the kyphectomy procedure.

## Conclusion

Our findings demonstrate the advantages using the Warner and Fackler technique, with follow-up revealing no loss of correction in the kyphotic angle using a posterior-only approach. Both short-term and midterm follow-ups indicate that this procedure corrects the deformity, maintains the reduction in the kyphotic angle, and improves the functional ability of the patient with high patient and parent satisfaction and minimal complications. Although blood loss was significant and operative time was extensive, this technique resulted in excellent correction of the sagittal plane deformity with minimal complications. The goals of surgery were universally achieved: hands-free sitting, an ability of the patients to lie supine, and an end to the recurrent skin breakdown over the apex of the gibbus.

## References

- [1] Martin J Jr, Kumar SJ, Guille JT, et al. Congenital kyphosis in myelomeningocele: results following operative and nonoperative treatment. *J Pediatr Orthop* 1994;14:323–8.
- [2] Banta JV, Hamada JS. Natural history of the kyphotic deformity in myelomeningocele. *J Bone Joint Surg Am* 1976;58:279.
- [3] Hoppenfeld S. Congenital kyphosis in myelomeningocele. *J Bone Joint Surg Br* 1967;49:276–80.
- [4] Mintz LJ, Sarwark JF, Dias LS, Schafer MF. The natural history of congenital kyphosis in myelomeningocele: a review of 51 children. *Spine* 1991;16:348–50.
- [5] Christofersen MR, Brooks AL. Excision and wire fixation of rigid myelomeningocele kyphosis. *J Pediatr Orthop* 1985;5:691–6.
- [6] Eckstein HB, Vora RM. Spinal osteotomy for severe kyphosis in children with myelomeningocele. *J Bone Joint Surg Br* 1972;54:328–33.
- [7] Sharrard WJW. Spinal osteotomy for congenital kyphosis in myelomeningocele. *J Bone Joint Surg Br* 1968;50:466–71.
- [8] Lindseth RE, Stelzer L Jr. Vertebral excision for kyphosis in children with myelomeningocele. *J Bone Joint Surg Am* 1979;61:699–704.
- [9] Heydemann JS, Gillespie R. Management of myelomeningocele kyphosis in the older child by kyphectomy and segmental spinal instrumentation. *Spine* 1987;12:37–41.
- [10] McCarthy RE, Dunn F, McCullough FL. Luque fixation to the sacral ala using the Dunn-McCarthy modification. *Spine* 1999;14:281–3.
- [11] Warner WC Jr, Fackler CD. Comparison of two instrumentation techniques in treatment of lumbar kyphosis in myelodysplasia. *J Pediatr Orthop* 1993;13:704–8.
- [12] Leatherman KD, Dickson RA. Congenital kyphosis in myelomeningocele: vertebral body resection and posterior spine fusion. *Spine* 1978;3:222–6.
- [13] Furdere S, Eysel P, Hopf C, Heine J. Sagittal static imbalance in myelomeningocele patients: improvement in sitting ability by partial and total gibbus resection. *Eur Spine J* 1999;8:451–7.
- [14] Huang TJ, Lubicky JP. Kyphectomy and segmental spinal instrumentation in young children with myelomeningocele kyphosis. *J Formos Med Assoc* 1994;93:503–8.
- [15] McCall RE. Modified luque instrumentation after myelomeningocele kyphectomy. *Spine* 1998;23:1406–11.
- [16] Nolden MT, Sarwark JF, Vora A, Gravhack JJ. A kyphectomy technique with reduced perioperative morbidity for myelomeningocele kyphosis. *Spine* 2002;27:1807–13.

- [17] McMaster MJ. The long-term results of kyphectomy and spinal stabilization in children with myelomeningocele. *Spine* 1988;13:417–24.
- [18] Lintner SA, Lindseth RE. Kyphotic deformity in patients who have myelomeningocele. *J Bone Joint Surg Am* 1994;76:1301–7.
- [19] Thomsen M, Lang RD, Carstens C. Results of kyphectomy with the technique of Warner and Fackler in children with myelodysplasia. *J Pediatr Orthop* 2000;9:143–7.
- [20] Akbar M, Bresch B, Seyler T, et al. Management of orthopaedic sequelae of congenital spinal disorders. *J Bone Joint Surg Am* 2009;91:81–100.